

Combined Topography-Guided Transepithelial PRK and CXL in Patients With Keratoconus

The combined procedure strengthens the cornea and regularizes the anterior surface.

BY MIRKO R. JANKOV II, MD, PhD; SLADJANA DELEVIC, MD; VESNA JOVANOVIC, MD, MS; EFEKAN COSKUNSEVEN, MD; AND SLOBODAN GOLUBOVIC, MD, PhD

Irregular astigmatism can occur naturally or due to trauma or surgery. Although technological and surgical skill improvements in modern refractive surgery have led to excellent outcomes, the occurrence of corneal irregularities postoperatively has been described.¹ Highly irregular corneas can also originate from corneal scars derived from injuries, previous inflammation, or surgical procedures such as penetrating keratoplasty, radial keratotomy, or arcuate cuts.²

Another more challenging cause of corneal irregularity is ectatic disease.³ Some of these diseases arise naturally, such as keratoconus and pellucid marginal degeneration, and others are surgically induced, such as iatrogenic ectasia after laser surgery. Common among all ectatic diseases is progression due to a previous structural weakening and thinning of the corneal stroma. Patients complain of decreased vision, glare, photophobia and monocular diplopia.

Once the patient is unable to use rigid contact lenses, there are few surgical alternatives for correction. Expectations are limited, and consequences may be unpredictable, both anatomically and functionally. In recent years, however, technological advances have led to two approaches: (1) corneal regularization based either on intrastromal corneal ring implantation⁴ or limited topography-guided excimer laser customized ablation treatment (T-CAT)⁵ or (2) corneal stabilization using corneal collagen crosslinking (CXL).⁶

Vision-correcting methods, such as laser treatment or intrastromal corneal ring implantation, attempt to regularize the front surface of the irregular cornea; however, they

maintain the existing unfavorable biomechanical status within the underlying stroma. In cases in which the irregular astigmatism is progressive, such as keratoconus, pellucid marginal degeneration, and laser-induced iatrogenic ectasia, the corneal stroma is structurally weakened, and some of these conditions may worsen following tissue ablation procedures.

Hence, to correct irregular astigmatism due to a biomechanically unstable cornea, a coadjuvant intervention such as CXL should be considered to potentially stabilize the cornea while regularizing the corneal surface.

CXL WITH RIBOFLAVIN AND UV-A

CXL with riboflavin and ultraviolet-A (UV-A) light administration is a technique that strengthens corneal tissue by using riboflavin as a photosensitizer and UV-A to increase the formation of intra- and interfibrillar covalent bonds through photosensitized oxidation.⁷ This technique is similar to photopolymerization in polymers, and through it biomechanical stabilization of the cornea is achieved.

The key indication for CXL is to inhibit the progression of corneal ectasias, such as keratoconus and pellucid marginal degeneration.⁸ CXL may also be effective in the treatment and prophylaxis of iatrogenic keratectasia resulting from LASIK.⁹ Beyond keratectasia, the technique can also be used in treating corneal melting conditions or infectious keratitis; CXL strengthens the collagenolytic cornea while the UV-A irradiation sterilizes the infectious agent.¹⁰

In the presence of 0.1% riboflavin acting as a photosensitizer, using an irradiance of 3 mW/cm² of UV-A, as much as

95% of UV-A light is absorbed within the cornea.⁷ Keratocyte apoptosis in the anterior corneal stroma to a depth of approximately 300 μm has been described, and a clear demarcation line between treated and untreated cornea has been shown.¹¹ Confocal microscopy studies also show that repopulation of keratocytes is already visible 1 month after treatment, and preoperative quantity and quality in terms of functional morphology is achieved within 6 months after treatment.¹²

TRANSEPIThELIAL TOPOGRAPHY-GUIDED PRK

T-CAT can achieve the goal of regularizing a distorted cornea by significantly reducing high astigmatism.¹³ However, additional thinning of the already biomechanically challenged cornea may be counterproductive, with the risk of worsening corneal biomechanical stability due to further thinning after tissue ablation.

Our surface ablation protocol is intended to reduce postoperative pain and haze by minimizing the inflammation reaction and minimizing increased sensitivity to UV-radiation injury.¹⁴ A 50- μm phototherapeutic keratectomy (PTK) at a 6.5-mm optical zone is used to remove the epithelium. Afterward, PRK with a minimal amount of tissue removal (less than 50 μm) and optical zones as small as 5.5 mm is planned, aiming at maximum cylinder reduction with minimal tissue removal to regularize the cornea.

COMBINED T-CAT PRK AND CXL

The key indications for use of this combined treatment method are to regularize distorted corneal optics, halt the progression of keratoconus, and achieve lasting visual rehabilitation. The goal is to synergize the effects of the two treatments. When planning combined sequential treatments, two main questions arise: (1) Which is the correct treatment order? (2) What is the right time interval between the treatments?

Regarding treatment sequence, concerns include whether the cornea pretreated with CXL will react to T-CAT PRK the expected way, or whether the effect will be altered because it is being applied now to a stiffer cornea. On the other hand, will CXL be safe when applied over a cornea additionally thinned by laser ablation?

If the plan is to first stabilize the cornea with CXL and later apply limited T-CAT transepithelial PRK, one should wait at least 6 months in between procedures, as by this time the cornea will have completed the repopulation and deactivation of keratocytes.¹² It is essential to wait past this period, as it is likely that a cornea with still activated keratocytes during the first few months after CXL will react excessively to excimer laser injury, resulting in an exaggerated

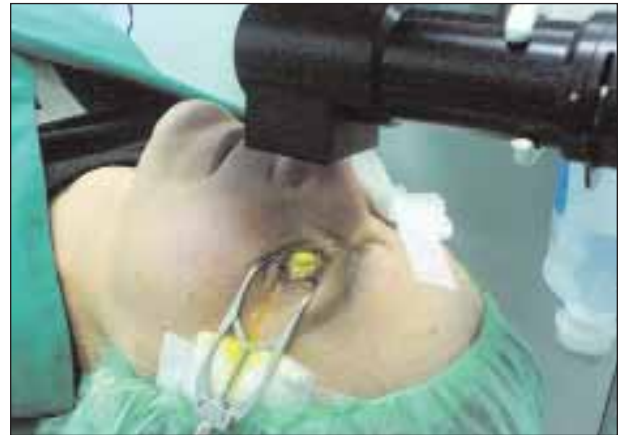

Figure 1. Treatment in progress; the cornea is soaked with riboflavin and irradiated by the UV lamp.

inflammatory response and thus haze.

It is probable that the ablation rate on a cornea previously treated with CXL would not be significantly altered in comparison with that of the normal cornea. Even if it were different, one would expect slight overcorrection, as the corneal collagen seems to be more compact in the first 6 months after the CXL treatment. This is the reason we recommend that approximately 80% of the refraction (mainly cylinder) should be treated at an optical zone of 6 or 5.5 mm and a transitional zone of 9 mm. One must also be sure not to surpass 50 μm of ablation depth at the deepest point.⁵

A single procedure, meaning an immediate sequence of T-CAT transepithelial PRK and CXL, would be without doubt more comfortable for both the patient and the surgeon. It is also easy to predict what the ablation outcome would be, as one would be applying the laser to virgin corneal tissue and there would be no need to remove the crosslinked cornea. Moreover, there would be less chance of PRK-induced scarring because the CXL would induce apoptosis of the keratocytes and thus eliminate the agents that would theoretically produce immunologic response.

However, corneal thickness becomes crucial in this case, as an excimer laser treatment, even with stromal removal limited to 50 μm , would additionally decrease the thickness of an already thin cornea. To avoid the danger of endothelial damage, we recommend intraoperative ultrasound contact pachymetry immediately after T-CAT PRK and the use of hypotonic riboflavin to expand the corneal thickness throughout the procedure.

Moreover, CXL alone additionally changes the corneal shape by flattening it up to 2.00 D of the keratometry value over several years,^{6,8,15-18} meaning that a planned laser treatment may be enhanced or even overflattened by additional CXL treatments later on. This is another reason why we rec-

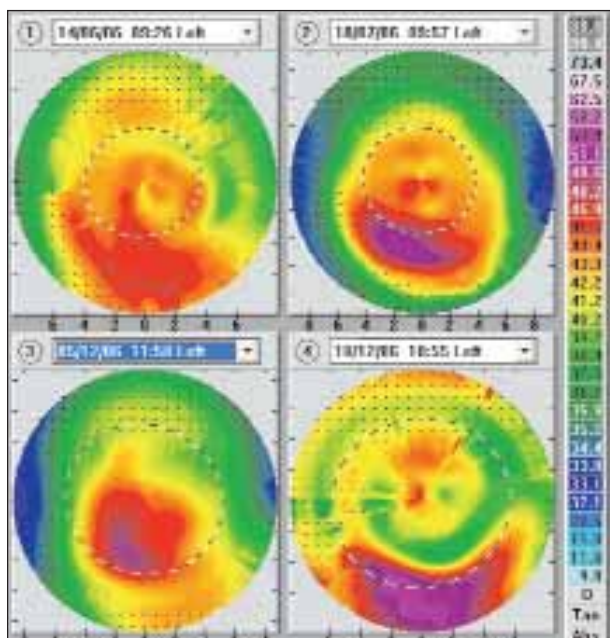


Figure 2. Serial computerized corneal topography: at the time of examination, right after the removal of the rigid gas permeable contact lens (upper left); 1 month after contact lens removal and the day of the CXL treatment (upper right); 5 months after CXL treatment and the day of T-CAT transepithelial PRK (lower left); 2 weeks after the T-CAT transepithelial PRK treatment (lower right).

commend treating the spherical component of the refraction only partially and planning 80% of the cylinder correction.

SURGICAL TECHNIQUE

The procedure is conducted under sterile conditions in an operating theater. Our surface ablation protocol aims to reduce postoperative pain and haze by minimizing the inflammation reaction and minimizing increased sensibility to UV-radiation injury. Vitamin C for protection against UV damage and haze formation¹⁸ and omega-3 fatty acids for improvement of the tear film, both 1 g daily, are given for 3 days before surgery and 6 months after the surgery. NSAID treatment with ibuprofen (Brufen; Galenika, Belgrade, Serbia) 600 mg four times daily is started 2 days before surgery and continued through day 3 postoperative. A prednisolone 50 mg (Pronison; Galenika) tablet is given orally as a single dose 30 minutes before the surgery. Diclofenac 0.1% (Voltaren; Novartis, Basel, Switzerland) and ciprofloxacin 0.3% (Marocen; Hemofarm, Vrsac, Serbia) eye drops are administered 15, 10, and 5 minutes before surgery.

The first drop of anesthetic, proparacaine 0.5% (Alcaine; Alcon Laboratories, Inc., Fort Worth, Texas) is applied during the preparation of the eyelids and the surgical field. Scleral (perilimbal) marks at the 3- and 9-o'clock positions,

defining a horizontal line, are placed with help of a slit lamp, using the light slit rotated into horizontal position. Before setting the marks, the patient's head tilt is adjusted so that both pupils are level (ie, positioned along the same horizontal line). The second drop of anesthetic is applied before introduction of the eye speculum under the laser microscope. Chilled balanced salt solution is applied to the cornea for 60 seconds to slow corneal metabolism.

Ablation using the Allegretto Wave excimer laser (WaveLight AG, Erlangen, Germany) is aligned onto the center of the pupil. A 50- μ m PTK at a 6.5-mm optical zone is applied to remove the epithelium uniformly. Immediately afterward, T-CAT PRK ablation of up to 50 μ m depth at a 5.5- to 6-mm optical zone is applied, followed by irrigation with chilled balanced salt solution for another 60 seconds.

Immediately after the transepithelial PRK and before CXL treatment, ultrasound pachymetry is performed over the deepithelialized cornea at approximately the thinnest point to ensure a minimal corneal thickness of 400 μ m. Riboflavin 0.1% solution in 20% dextran (Peschkemed, Huenenberg, Switzerland) is applied to the cornea every 3 minutes for 30 minutes. For corneas thinner than the safety limit, 30-minute instillation of hypotonic riboflavin 0.1% without dextran is applied until the cornea has reached at least 380 μ m thickness.

UV-A irradiation is performed using an optical system (Koehler illumination) consisting of an array of seven UV-A diodes with a potentiometer in series to allow regulation of voltage (UV-X; Peschkemed; Figure 1). Irradiance is performed for 30 minutes at 3 mW/cm², corresponding to a surface dose of 5.4 J/cm². During treatment, riboflavin solution and topical anesthetic proparacaine 0.5% are applied every 2 to 3 minutes to saturate the cornea with riboflavin and moisten it.

After the treatment, dexamethasone with tobramycin ointment (Tobradex; Alcon Laboratories, Inc.) and topical ofloxacin 0.3% (FloXal; Bausch & Lomb, Rochester, New York) are applied. A bandage contact lens is fitted to the corneal surface and removed after reepithelialization, typically on day 3 postoperative. The patient is given the topical steroid dexamethasone phosphate 0.1% (Maxidex; Alcon-Couvreur, Belgium) four times daily, with gradual decrease of dosage over the following 2 months.

CASE PRESENTATIONS

Case 1: CXL first, T-CAT transepithelial PRK later. A 36-year-old woman who had worn rigid gas permeable contact lenses for 20 years reported to our service because of contact-lens intolerance. Her BCVA with contact lenses was 1.0 in both eyes. Papillary reaction was observed on the upper tarsal conjunctiva, with red eye and corneal punctate ero-

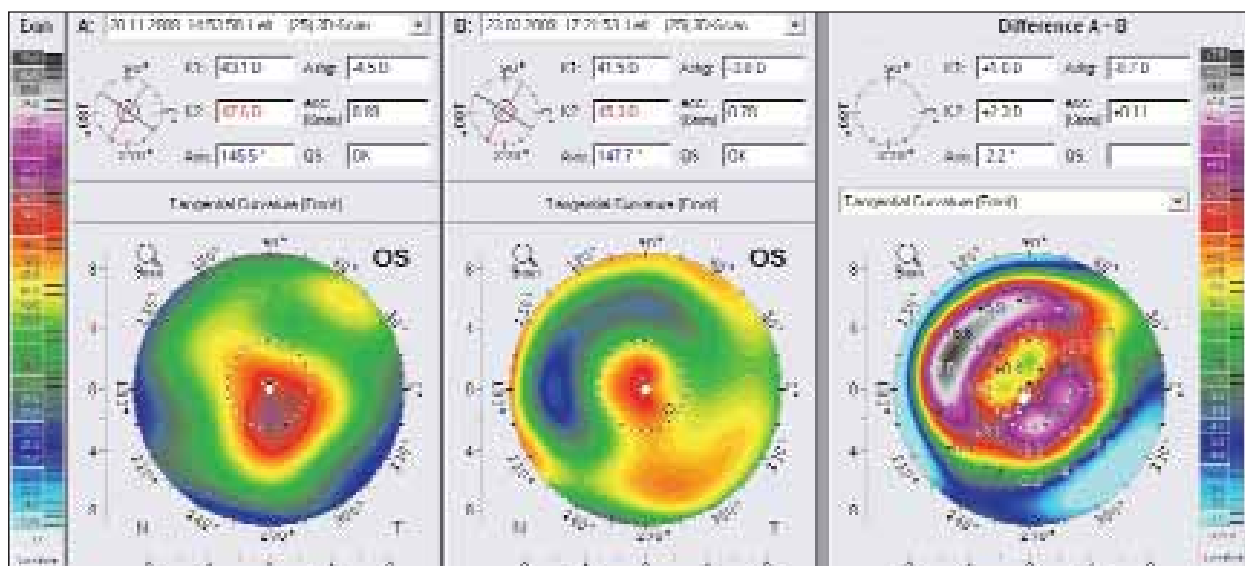


Figure 3. Computerized corneal Scheimpflug tomography: (left) before and (center) after the combined T-CAT transepithelial PRK-CXL treatment. Difference map is at right.

sions. At the examination, her BCVA in the right eye was 0.6 with refraction of $-2.00 -1.50 \times 90^\circ$ and in the left was 0.4 with refraction of $-2.50 -1.75 \times 100^\circ$. Ultrasound pachymetry was 493 and 474 μm in the right and left eyes respectively, and her computerized corneal topography can be seen in Figure 2.

After 1 month of contact lens abstinence, a typical pattern of keratoconus could be appreciated on corneal topography. At that time bilateral CXL treatment was performed. Almost 5 months after the CXL treatment, BCVA in the right eye was 1.0+ with refraction of $-3.25 -1.00 \times 90^\circ$ and in the left eye 0.6 with $-3.50 -1.50 \times 100^\circ$. As the patient was contact-lens intolerant, T-CAT transepithelial PRK was performed in the left eye. After 2 weeks, UCVA reached 0.8, and BCVA was 1.0+ with refraction of $-0.75 -0.50 \times 90^\circ$.

Case 2: T-CAT transepithelial PRK followed immediately by CXL. A 26-year-old woman with a 10-year history of keratoconus became contact-lens intolerant 1.5 years

ago. She had been treated at another center with successive CXL and implantation of Ferrara Rings (Ferrara Ophthalmics, Belo Horizonte, Brazil) 1 year ago in her right eye. This resulted in UCVA in the right of 0.3 and BCVA of 0.6 with refraction of -0.75 D sphere, which did not improve with pinhole. Her left eye had UCVA of 0.1 and BCVA of 0.3+ with refraction of $-1.75 -1.75 \times 150^\circ$, achieving 0.6 with pinhole.

In her left eye, we performed T-CAT transepithelial PRK followed by immediate application of CXL. Three months after treatment, her UCVA was 0.5 and BCVA was 0.6 with refraction of $-0.50 -1.25 \times 155^\circ$. Topography can be seen in Figure 3.

CONCLUSIONS

Treatment of keratoconus with a combination of CXL and excimer laser topography-guided transepithelial PRK is possible. The aim of this combined treatment is regularization of the cornea and significant reduction of irregular astigmatism rather than complete elimination of spherical refractive error. Thus, an ablation depth of up to 50 μm with small optical zones (6 or 5.5 mm) and larger transition zones (9 mm) is recommended.

With sequential CXL followed by T-CAT transepithelial PRK, an interval of at least 6 months should be allowed between the two treatments. Coadjuvant T-CAT transepithelial PRK immediately followed by CXL is more comfortable for the patients; however, it is suitable for thicker corneas or earlier stages of keratoconus. ■

TAKE-HOME MESSAGE

- In patients with irregular astigmatism due to keratoconus, treatments such as PRK or corneal rings can regularize the front surface of the cornea, but they do not address the underlying unfavorable biomechanical status of the stroma.
- A coadjuvant intervention with CXL can potentially stabilize the cornea and regularize the corneal surface.
- With combined CXL and topography-guided transepithelial PRK, Dr. Jankov and colleagues aim to regularize the cornea and reduce irregular astigmatism, rather than completely eliminating spherical refractive error.

Mirko R. Jankov II, MD, PhD, practices at LaserFocus Centre for Eye Microsurgery, Belgrade, Serbia. Dr. Jankov states that he is a paid consultant to WaveLight Laser Technologie AG. He may be reached at e-mail: visioncare@mac.com.



Sladjana Delevic, MD, is with Oculus Specialized Hospital for Ophthalmology, Belgrade, Serbia. Dr. Delevic states that she has no financial interests in the products or companies mentioned.

Vesna Jovanovic, MD, MS, practices at LaserFocus Centre for Eye Microsurgery, Belgrade, Serbia. Dr. Jovanovic states that she has no financial interests in the products or companies mentioned.

Efekan Coskunseven, MD, is with the Dunya Eye Hospital, Istanbul, Turkey. Dr. Coskunseven states that he has no financial interests in the products or companies mentioned.



Slobodan Golubovic, MD, PhD, is with Oculus Specialized Hospital for Ophthalmology, Belgrade, Serbia. Dr. Golubovic states that he has no financial interests in the products or companies mentioned.

1. Hersh PS, Fry KL, Bishop DS. Incidence and associations of retreatment after LASIK. *Ophthalmology*. 2003;110(4):748-754.
2. Lindstrom RL. The surgical correction of astigmatism: a clinician's perspective. *Refract Corneal Surg*. 1990;6(6):441-454.
3. Kennedy RH, Bourne WM, Dyer JA. A 48-year clinical and epidemiologic study of keratoconus. *Am J Ophthalmol*. 1986;101(3):267-273.
4. Coskunseven E, Kymionis GD, Tsiklis NS, et al. One-year results of intrastromal corneal ring segment implantation (KeraRing) using femtosecond laser in patients with keratoconus. *Am J Ophthalmol*. 2008;145(5):775-779.
5. Kanellopoulos AJ, Binder PS. Collagen cross-linking (CCL) with sequential topography-guided PRK: a temporizing alternative for keratoconus to penetrating keratoplasty. *Cornea*. 2007;26(7):891-895.
6. Coskunseven E, Jankov MR, Hafezi F. Contralateral eye study of corneal collagen cross-linking with riboflavin and UVA irradiation in patients with keratoconus. *J Refract Surg*. 2009;25(4):371-376.
7. Spoerl E, Huhle M, Seiler T. Induction of cross-links in corneal tissue. *Exp Eye Res*. 1998;66(1):97-103.
8. Wollensak G, Spoerl E, Seiler T. Riboflavin/ultraviolet-A-induced collagen crosslinking for the treatment of keratoconus. *Am J Ophthalmol*. 2003;135(5):620-627.
9. Hafezi F, Wittfang R, Kanellopoulos J, Seiler T. Corneal collagen crosslinking with riboflavin and ultraviolet A to treat induced keratectasia after laser in situ keratomileusis. *J Cat Refract Surg*. 2007;33(12):2035-2040.
10. Schnitzler E, Spoerl E, Seiler T. Irradiation of cornea with ultraviolet light and riboflavin administration as a new treatment for erosive corneal processes, preliminary results in four patients. [Article in German] *Klin Monatsbl Augenheilkd*. 2000;217(3):190-3.
11. Seiler T, Hafezi F. Corneal cross-linking-induced stromal demarcation line. *Cornea*. 2006;25(9):1057-1059.
12. Mazzotta C, Balestrazzi A, Traversi C, et al. Treatment of progressive keratoconus by riboflavin-UVA-induced cross-linking of corneal collagen: ultrastructural analysis by Heidelberg Retinal Tomograph II in vivo confocal microscopy in humans. *Cornea*. 2007;26(4):390-397.
13. Jankov MR, Panagopoulou SI, Tsiklis NS, Hajitanasis GC, Aslanides IM, Pallikaris IG. Topography-guided treatment of irregular astigmatism with the WaveLight excimer laser. *J Refract Surg*. 2006;22(4):335-344.
14. Stojanovic A, Wang L, Jankov MR, Nitter TA, Wang Q. Wavefront optimized versus custom-Q treatments in surface ablation for myopic astigmatism with the WaveLight Allegretto Laser. *J Refract Surg*. 2008;24(8):779-789.
15. Jankov MR, Hafezi F, Beko M, et al. Corneal cross-linking for the treatment of keratoconus: preliminary results. [Article in Portuguese] *Arq Bras Oftalmol*. 2008;71(6):813-818.
16. Agrawal VB. Corneal collagen cross-linking with riboflavin and ultraviolet – a light for keratoconus: results in Indian eyes. *Indian J Ophthalmol*. 2009;57(2):111-114.
17. Wittig-Silva C, Whiting M, Lamoureux E, Lindsay RG, Sullivan LJ, Snibson GR. A randomized controlled trial of corneal collagen cross-linking in progressive keratoconus: preliminary results. *J Refract Surg*. 2008;24(7):S720-725.
18. Vinogueria P, Albe E, Trazza S, et al. Refractive, topographic, tomographic, and aberrometric analysis of keratoconic eyes undergoing corneal cross-linking. *Ophthalmology*. 2009;116(3):369-378.
19. Stojanovic A, Ringvold A, Nitter T. Ascorbate prophylaxis for corneal haze after photorefractive keratectomy. *J Refract Surg*. 2003;19:338-343.